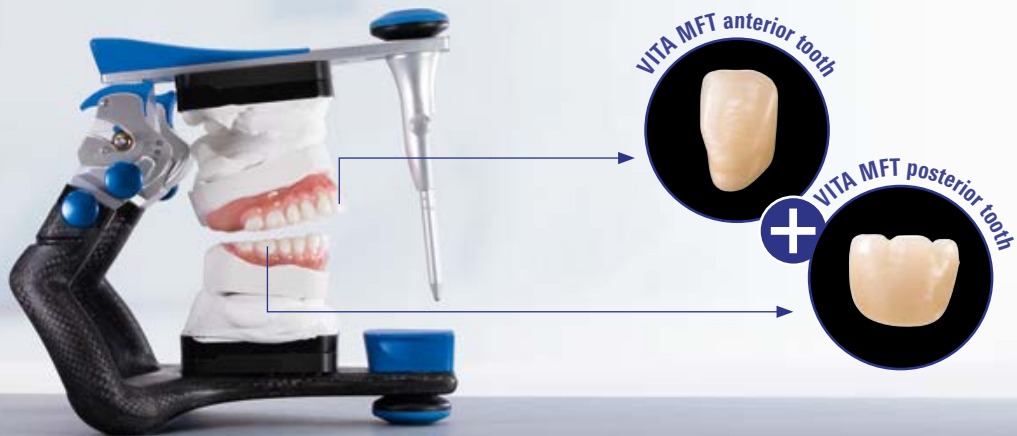



VITA MFT®

Setup guide

For solid, esthetic results,
thanks to natural shape.

VITA MFT® anterior tooth

Basic anterior teeth made of HC polymer material for
partial and full dentures

- **Reliable production of solid, esthetic dentures**

thanks to natural incisal edge characteristics
and angle features

- **Simple replication of a natural play of light**

thanks to a balanced enamel-dentine relationship,
integrated mamelons and texture

- **Reliable shade reproduction**

thanks to shade accuracy with the VITA shade standard
(VITA classical A1–D4® and VITA SYSTEM 3D-MASTER)

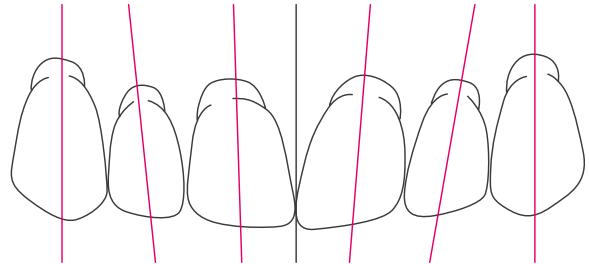


Setup of the upper anteriors.

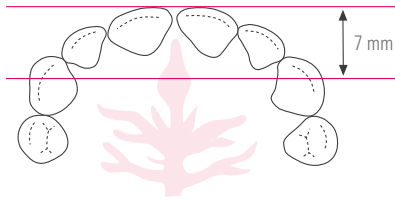
A natural anterior tooth setup is achieved with the following features:

- The central incisors are upright.
- The cervical portion of the lateral incisors is inclined distally.
- The canines are tendentially upright, with the tooth neck inclined vestibularly.
- The incisal edges of the upper central incisors run parallel to and are situated approximately +/- 1-2 mm above the occlusal plane.
- The incisal edges of the upper lateral incisors run parallel to the occlusal plane and do not touch it.
- The tips of the canines are situated approximately on the occlusal plane.

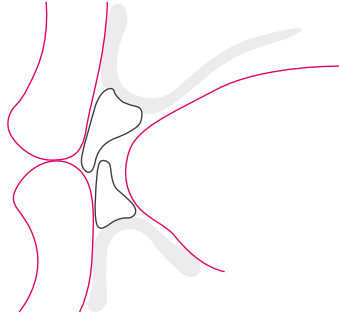
The teeth are mostly positioned according to the atrophy of the upper jaw in front of the alveolar ridge – with their labial surfaces above the vestibule.



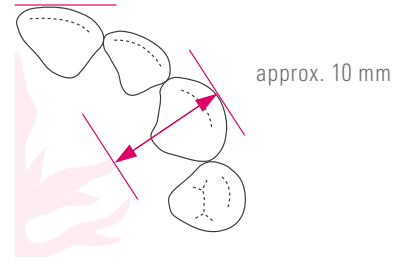
Setup of the upper anteriors.



In a normal bite, the upper anterior teeth are about 7 mm from the center of the incisive papilla.

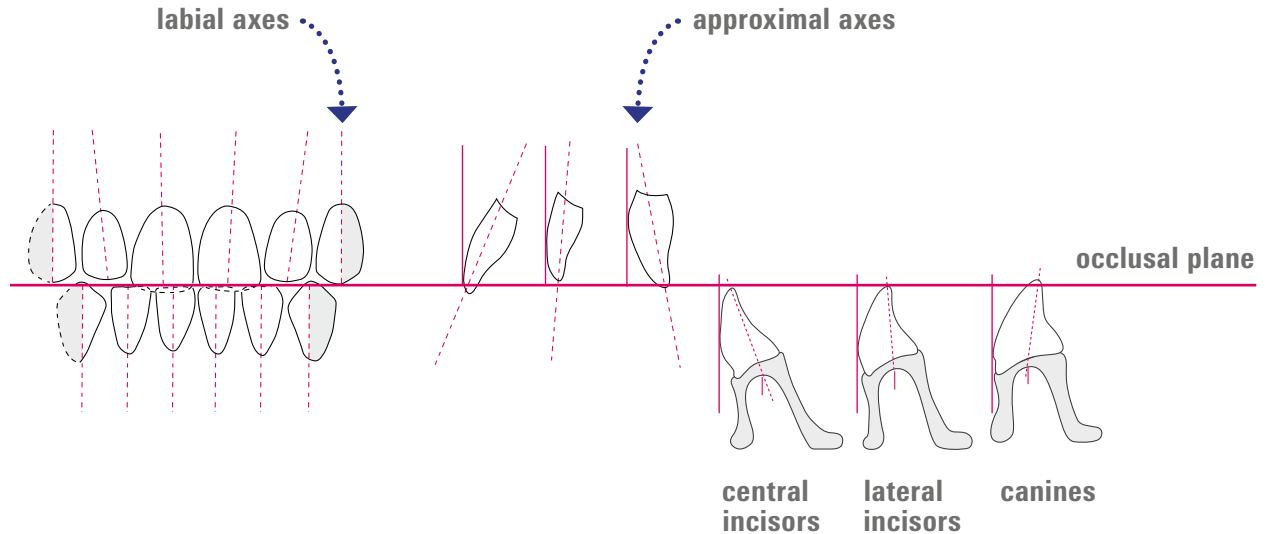


The labial surfaces of the upper anteriors provide support to the upper lip. The incisal edges of the central incisors ensure a harmonious lip contour.

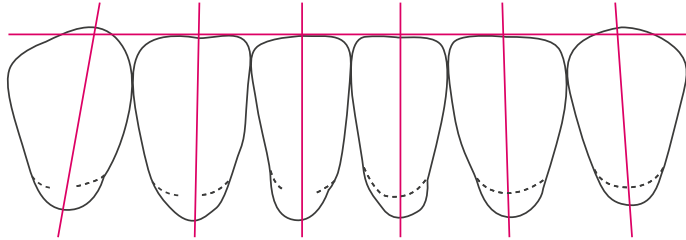


The tips of the two canines are positioned at a distance of approx. 10 mm from the end of the first pair of palatal folds.

Setup of anterior teeth in relation to the occlusal plane.



Setup of the lower anteriors.



Characteristics for the setup of the lower anterior teeth:

- The incisal edges of the lower incisors are level with, and run parallel to, the occlusal plane.
- The tips of the canines are situated slightly above the occlusal plane.

From the labial view:

- The central incisors are straight and upright.
- The lateral incisors show a slight mesial inclination.
- The canines are straight or show a slight mesial inclination.
- The distal facet of the canine points in the direction of the molars

Rule of thumb for tooth neck positions

When positioning the tooth necks on the alveolar ridge, the following rule of thumb can be applied: the central incisors are on, the lateral incisors at and the canines are outside of the lower alveolar ridge path.

For simplified setup due to function-optimized occlusal surfaces.

VITA MFT® – Posterior teeth

Basic posterior teeth made of HC polymer with multifunctional occlusal surfaces of full and partial dentures

- **Simplified setup of dentures**

through predefined contact points for automatic occlusion

- **High degree of setup reliability**

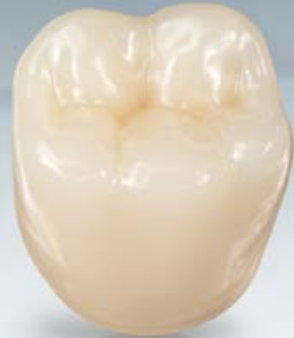through function-optimized occlusal surfaces for a controlled centric occlusion

- **Reduced grinding work**

thanks to optimized basal design

- **Can be reliably used for all prosthetic concepts**

thanks to the multifunctional occlusal surface design

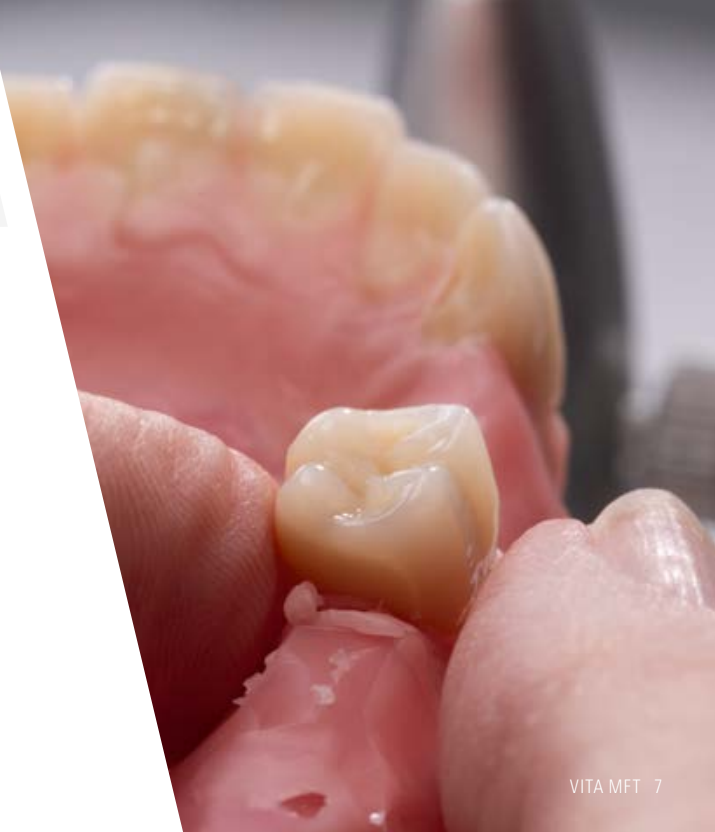

The significance of lingualized occlusion in dental prosthetics.

The main characteristic of lingualized occlusion is the optimization of the positional stability of a dental prosthesis.

In both static and dynamic occlusion, it is important to ensure that all occlusal forces in close occlusal contact are aligned towards the center.

When setting up the teeth, the focus should be on the central palatal contact relationship.



The significance of lingualized occlusion in dental prosthetics.

Positive static and medical outcomes:

- **Prosthetic restorations for patients are significantly improved** when faced with difficult statics, or when there is a strong divergence between conditions in the upper and lower jaw. This means that in the case of larger lower, and smaller upper dental arches – which were often solved by setting up a crossbite – the teeth can be set up further buccally without compromising the stability of the prosthesis. This can also help avoid the buildup of pressure areas.
- Thanks to the **axial direction of force**, this concept prevents excessive **strain on the rest area of the prosthesis**, which is beneficial, particularly in the case of implant prosthetics. This is mainly due to the fact that this offers protection, to a great extent, against horizontal shear forces.
- The greater accuracy in the positioning of the mastication elements in the **"neutral zone" (i.e., muscular balance)**, leads to better cheek contact of the teeth and noticeably more tongue space for the patient. This cheek contact prevents the formation of a food bolus in the vestibular area and helps horizontally stabilize the prosthesis.

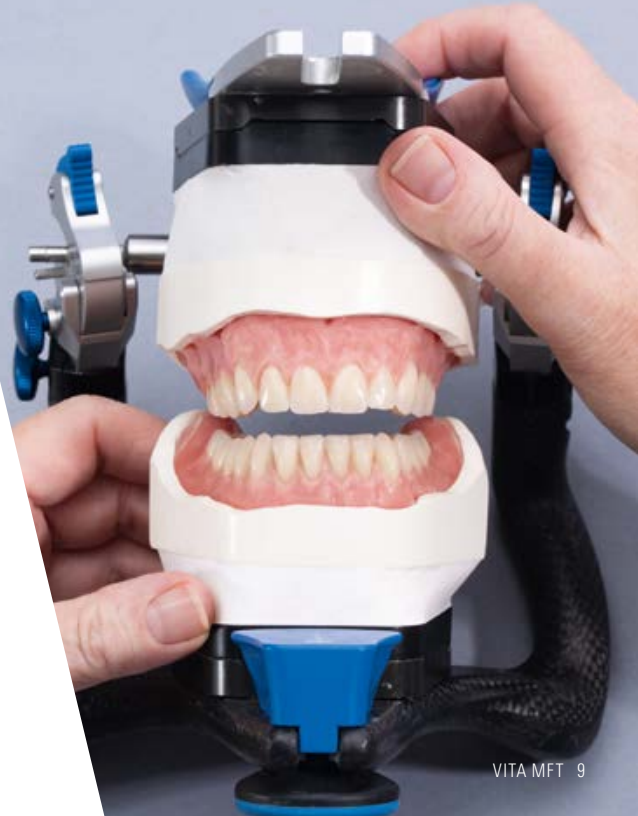The significance of lingualized occlusion in dental prosthetics.

For the patient, this means:

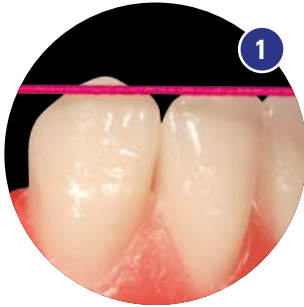
- Increased comfort due to enlargement of the tongue space
- Reduction of cheek biting due to gaps in buccal contacts
- Reduction of pressure points
- Small regulatory control movements (Dr. Hildebrandt) with little disclusion are possible

Benefits for the dental technician:

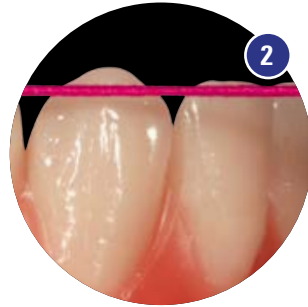- Clearly reproducible contact relationships
- Comprehensible and controllable setup criteria
- Efficient, time saving and safe to set up



Setup of the lower anteriors and the first premolar.

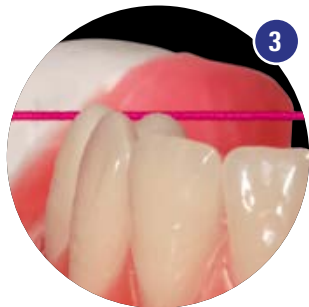

The lower incisors are aligned to the occlusal plane with the labial surfaces pointing in the direction of the upper anterior sulcus. The canines stand in their longitudinal axis at right angles to the occlusal plane and should be situated approximately one millimeter above the occlusal plane.

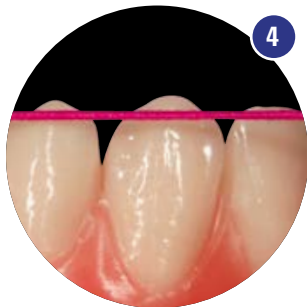

The setup of the first lower premolar is identical to the canine. As a result, it is aligned at right angles to the occlusal plane. The mesial portion of the buccal facet is above the occlusal plane, as is the canine; the distobuccal portion follows the line of the occlusal plane

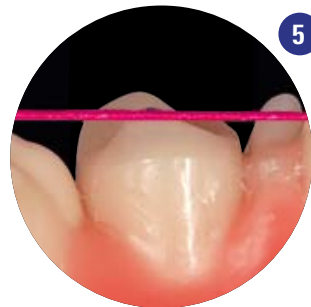Checking the setup of the first lower premolar.



The mesio Buccal area is situated above the occlusal plane



The setup of the disto Buccal area follows the line of the occlusal plane

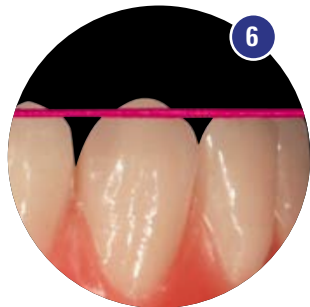

The lingual cusp tip is located in the area of the occlusal plane

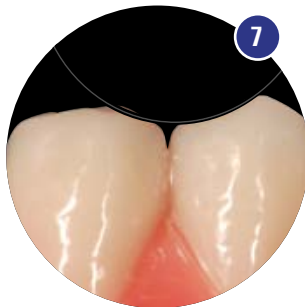
The tooth axis is aligned at right angles to the occlusal plane

Note: In order to achieve the optimal relationship between the contact points, the dominance of the lingual cusp of the lower first premolar was designed in a function-oriented manner. See also **Figs. 16, 21, 23.**

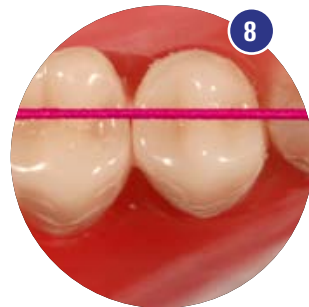
Setup of the second lower premolar.



The neck of the second lower premolar shows a slight distal inclination in comparison to the first premolar.

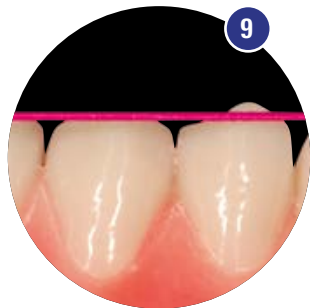

Mesially to the first premolar, a harmonious rounded contour should be established that facilitates appropriate functional setup of the first upper premolar. See also **Fig. 19**.

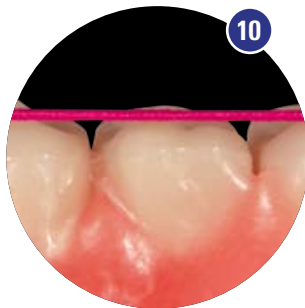

The lingual cusp is aligned to the occlusal plane. See also **Figs. 10, 13**. The setup follows an imaginary line, which runs from the canine distal facet, through the central fissures of the premolars and molars. See also **Fig. 11**.

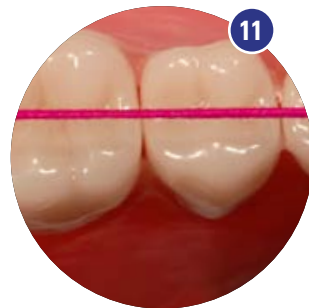
Setup of the first lower molar. (without the setup of the second lower molar)



In line with the orientation of the second premolar, the first molar is raised distally, such that the distobuccal cusp is at the level of the canine and the first premolar, i.e., it is situated approx. 1 mm above the occlusal plane: **Fig. 9.**

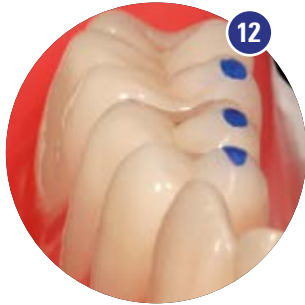

The lingual cusps are aligned with the occlusal plane: **Fig. 10.** See also **Fig.13.**

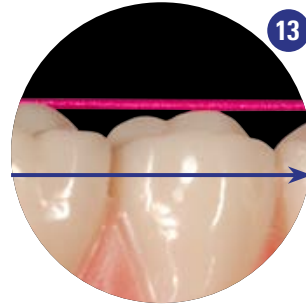


The setup follows an imaginary line which runs from the canine distal facet through the central fissures of the premolars and molars: **Fig.11.**

Setup of the lower posteriors.

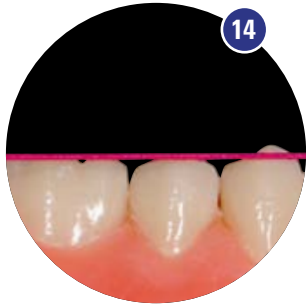

Aids for checking the setup: In addition to checking using a rubber thread, markings on the lingual cusp tips of the lower VITA MFT posteriors (**important: no contact points**) can be used to easily verify the correct gradient of the posterior setup, as well as the alignment of the posterior teeth, in terms of their uniform height with regard to the occlusal plane.

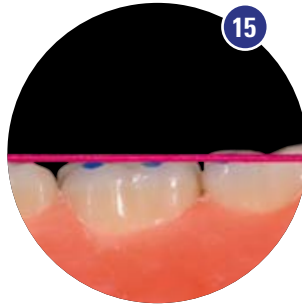


This **view clearly shows the cuspal progression** of the setup from lingual to buccal, as well as from buccal to lingual. It shows that all cusps up to the buccal cusp of the first premolar and the distal cusps of the first molar are aligned to the occlusal plane.

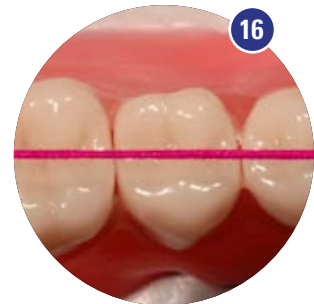Setup of the first lower molar. (with the setup of the second lower molar)



In this case, continuing the trend of the second premolar, the first molar is set up flat (i.e., with its distobuccal cusp touching the occlusal plane).

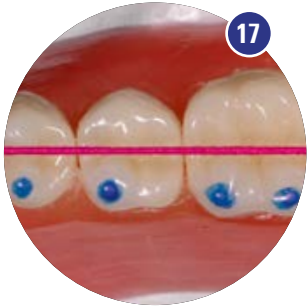


Also the lingual cusps are in contact with the occlusal plane.

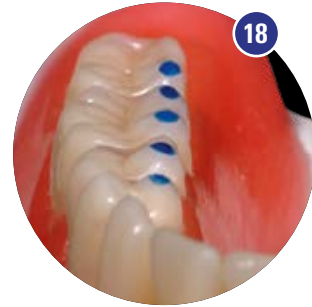

The setup follows an imaginary line which runs from the distal facet of the canine through the central fissures of the premolars and molars.

Setup of the lower posteriors.

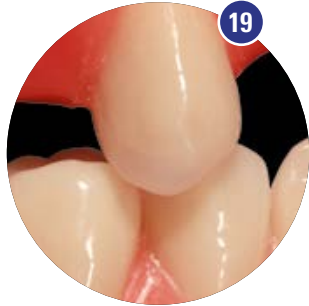

In addition to checking using a rubber thread, markings on the lingual cusp tips of the lower VITA MFT posteriors can be used to easily verify the correct gradient of the posterior setup.

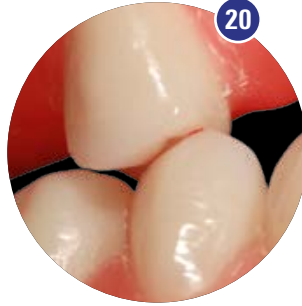

This perspective shows the straight lingual progression of the cusps from mesial to distal.

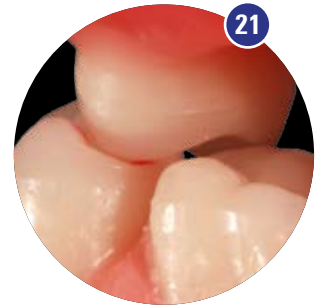Setup of the upper posteriors – first upper premolar.



The first upper premolar is positioned at a right angle to the occlusal plane, resulting in a tooth-to-tooth relationship with its antagonist. See also **Figs. 4, 7.**

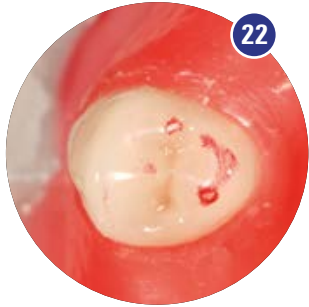


The first upper premolar is set up slightly opened towards the buccal side, the first lower premolar has contact on the mesial marginal ridge, and in the area of the mesiocentral fossa of the first upper premolar.



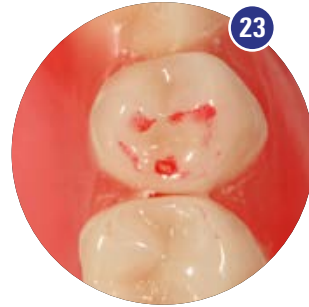Palatally, the upper first premolar achieves secure contact in the central fossa of its lower antagonist to improve static occlusion.

First upper premolar: contact relationship.



The mutual contact relationship of the first premolars is clear, unmistakable and always reproducible:

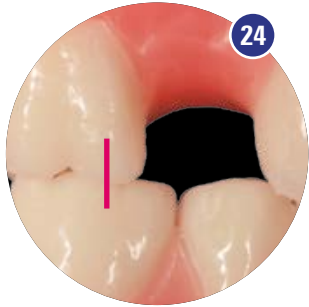
The mesial marginal ridge of the palatal cusp in the upper jaw forms a clear mutual tripodization (three-point support) with the distolingual fossa of the lower premolar.



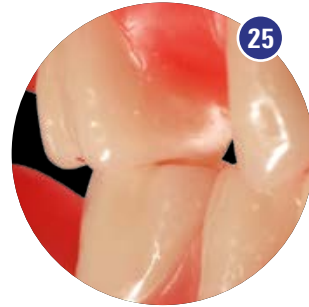It is important to ensure sufficient buccal freedom.

This is required in order to benefit from the free space in the molar area. See also **Fig. 20**.

Setup of the first upper molar.

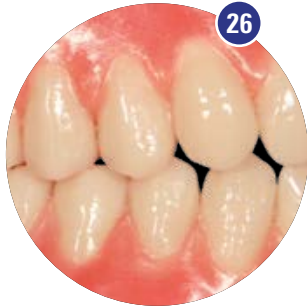

With a reliable and specific setup pattern of the teeth (highest number of reference points), **it is advantageous to set up the first molar before the second premolar.** For this purpose, the first molar, like the premolars, set up in a tooth-to-tooth relationship.

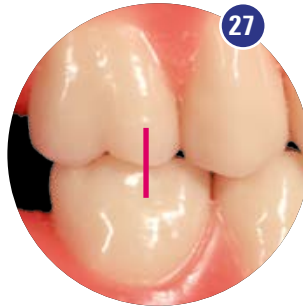

Besides the centric palatal contact relationship, care should also be taken to ensure **sufficient free space buccally.** A space of between 1 and 2 mm is generally required. See also **Figs. 26, 27, 28.**

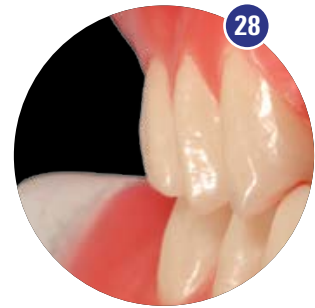
Setup of the second upper premolars.



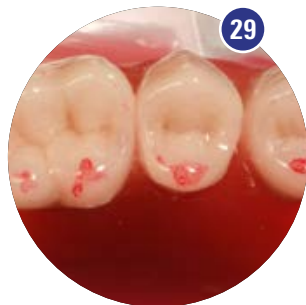The second upper premolar is then set up in the remaining space. From a functional viewpoint, it is also in a tooth-to-tooth relationship and approximately **at a right angle to its antagonist** in the lower jaw.



The second upper premolar is also set up with buccal freedom. According to its size, this is positioned between the first premolar and the first molar. The goal is to achieve a **harmonious transition** in which the free space is increased successively from the first premolar to the last molar.



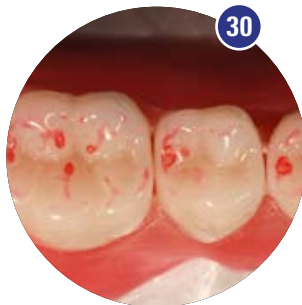Contact relationships of the upper to the lower posteriors.



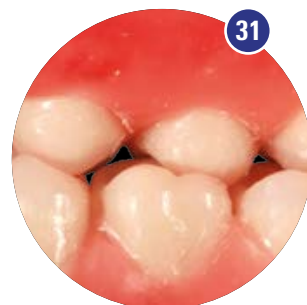
The contact relationship of the
VITA MFT posterior tooth:

Fig. 29: The focus is mainly on the palatal support.

Fig. 30: The palatal cusps bite precisely into the fossae of the mandibular teeth.



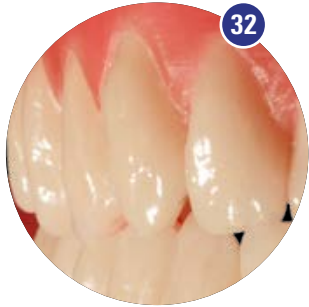This setup promotes restoration stability, improves statics and expands the tongue space. The forces on the mucous membrane and bones underneath are minimized.



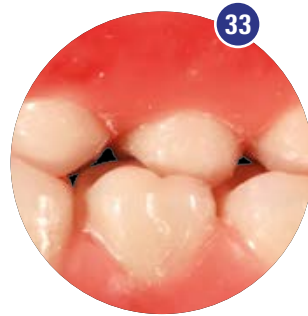This is generally **beneficial in protecting the denture bearing area** and can be an important factor regarding the survival rate of placed implants.

Fig. 31: The palatal view shows ideal intercuspation.

The completed restoration.

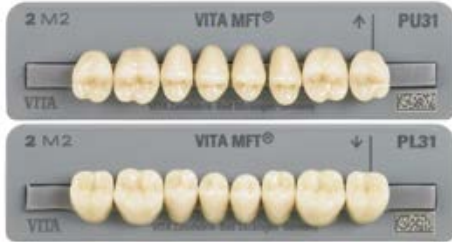

The mesial, buccal and palatal view of the completed setup show the connection between clear, reproducible function and **esthetic harmony**.



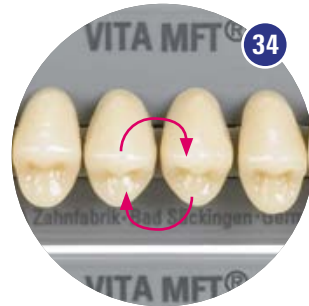The **excellent (highly precise) palatal contact relationship** is due to the consistent application of the principles of lingual occlusion, according to Prof. Dr. Gerber. At the same time, the requirements regarding the correct functional alignment of the teeth are fulfilled through a statically correct setup.

Special tooth moulds.



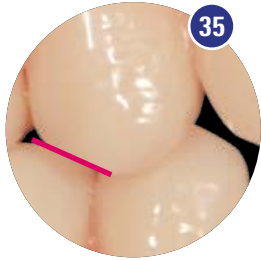
The first upper premolar in particular, plays a key part in complete denture prosthetics.

Just like natural dentition, in addition to providing centric palatal support, it helps guide the mandible, while sliding into the centric position.

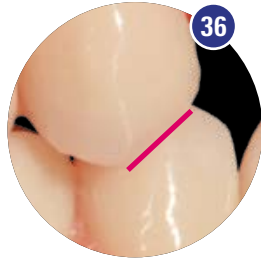


To make this guidance more active or more passive, the first upper premolar can be exchanged, quadrant-wise, prior to setting up. No change is made to the setup of the lower teeth. The centric contact relationship of the premolars remains virtually unchanged.

Exchange 14/24.

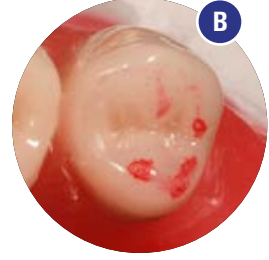
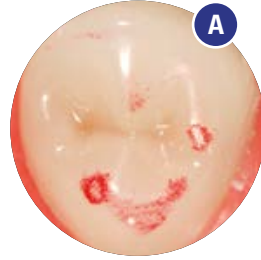


Tooth 14 straight from the teeth set



Exchanged tooth 24

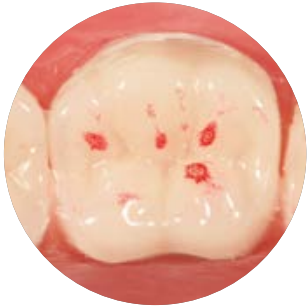As illustrated, a further essential difference can be seen if tooth 14 is exchanged with tooth 24. **Fig. 35:** The occlusal contact surface on the first premolar is clearly recognizable from the distobuccal view. **Fig. 36:** When tooth 14 is replaced by tooth 24, this occlusal contact surface changes from distal to mesial. This increases the free space buccally around the centric position and strengthens the palatal contact relationship.



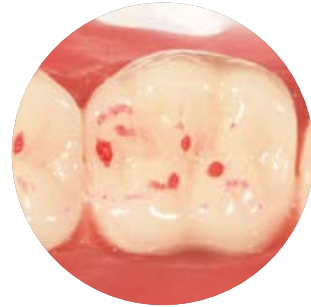
This makes **virtually no difference** to the alignment of the tooth axis or the tooth-to-tooth relationship.

Figs. A and B: The appearance of the contact relationship remains identical in its arrangement, despite the exchange of a tooth.

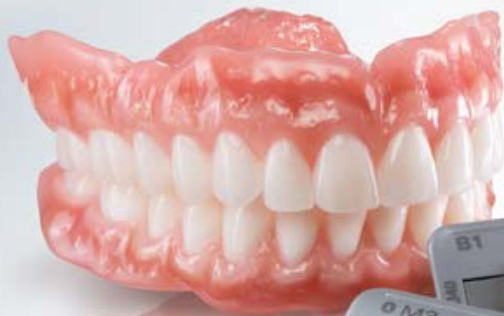Safely reaching the contact points.



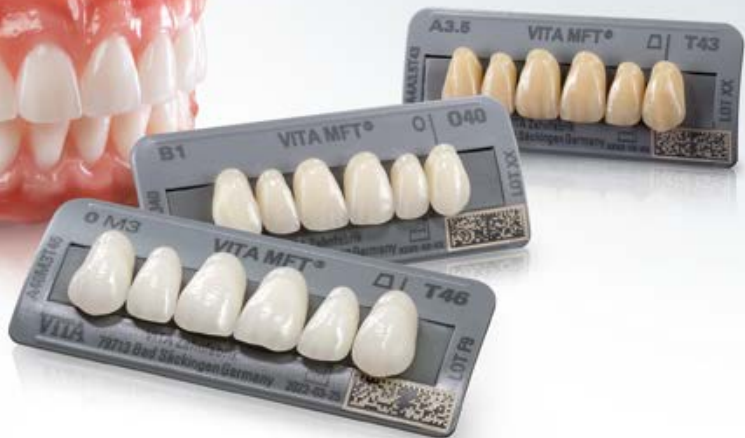Its defined centric occlusion with the stable tripodization of the molars in the mesial, central and distal area of the lower fossa, highlights the multifunctionality of VITA MFT.



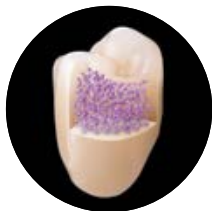In the case of a mesial shift, the tripod function remains fully intact; this plays a decisive part in both the combined technique and in implant prosthetics.



The finished prosthesis
with VITA MFT®



VITA MFT® – Made of top material.



PMMA pearls



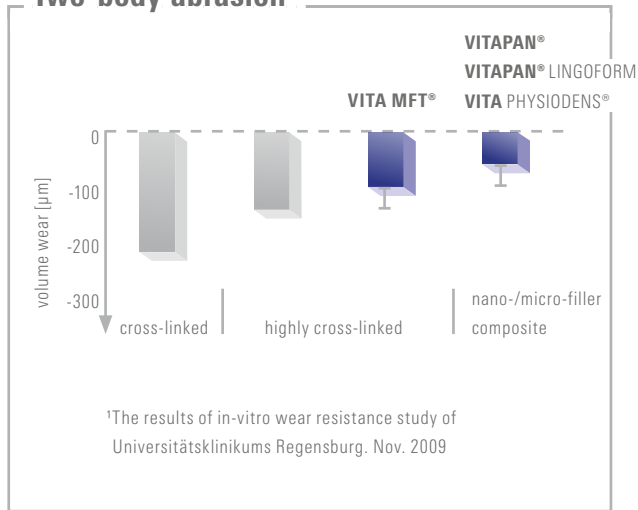
Cross-linked
PMMA

Convincing material quality

The three-dimensional, highly cross-linked PMMA material, ensures exceptional material density and very good biocompatibility throughout.

- Good mechanical stability and surface resistance
- Shade-stable
- Tissue-friendly
- very good polishability
- First-class bond with the prosthesis base

Two-body abrasion¹



Sources.

Hofmann-Axthelm "Lexikon der Zahnmedizin"

Hohmann-Hielscher "Lehrbuch der Zahntechnik"
Quintessenz Verlag 2001

Stuck /Horn "Zahnaufstellung in der Totalprothetik"

Parsche E. "Funktionslehre/Biomechanik" Graz 2006

Gründler, H. /Stüttgen, U. "Die Totalprothese"
Verlag Neuer Merkur GmbH 1995

Linke u.a., 2001

Tschirch, 1966

VITA, "A Guide to Complete Denture Prosthetics," 2010



We would like to thank...

Mr. Karl-Heinz Körholz for his support
in compiling this setup guide.

We are happy to help.

Hotline Sales Support

Phone +49 7761 562-884

Fax +49 7761 562-299

8 a.m. to 5 p.m. CET

Email info@vita-zahnfabrik.com

Technical Hotline

Phone +49 7761 562-222

Fax +49 7761 562-446

8 a.m. to 5 p.m. CET

Email info@vita-zahnfabrik.com



Please note:

Our products must be used according to the instructions for use. We accept no liability for any damage resulting from incorrect handling or usage. The user is furthermore obliged to check the product before use with regard to its suitability for the intended area of application. We cannot accept any liability if the product is used in conjunction with materials and equipment from other manufacturers that are not compatible or not authorized for use with our product and this results in damage. The VITA Modulbox is not necessarily a component of the product. Publication of this product brochure: 01/24

After the publication of this information of use, any previous versions become obsolete. The current version can be found at www.vita-zahnfabrik.com

VITA Zahnfabrik has been certified and the following products bear the CE mark

CE 0124: VITA MFT®

The products/systems of other manufacturers mentioned in this document are registered trademarks of the respective manufacturers.

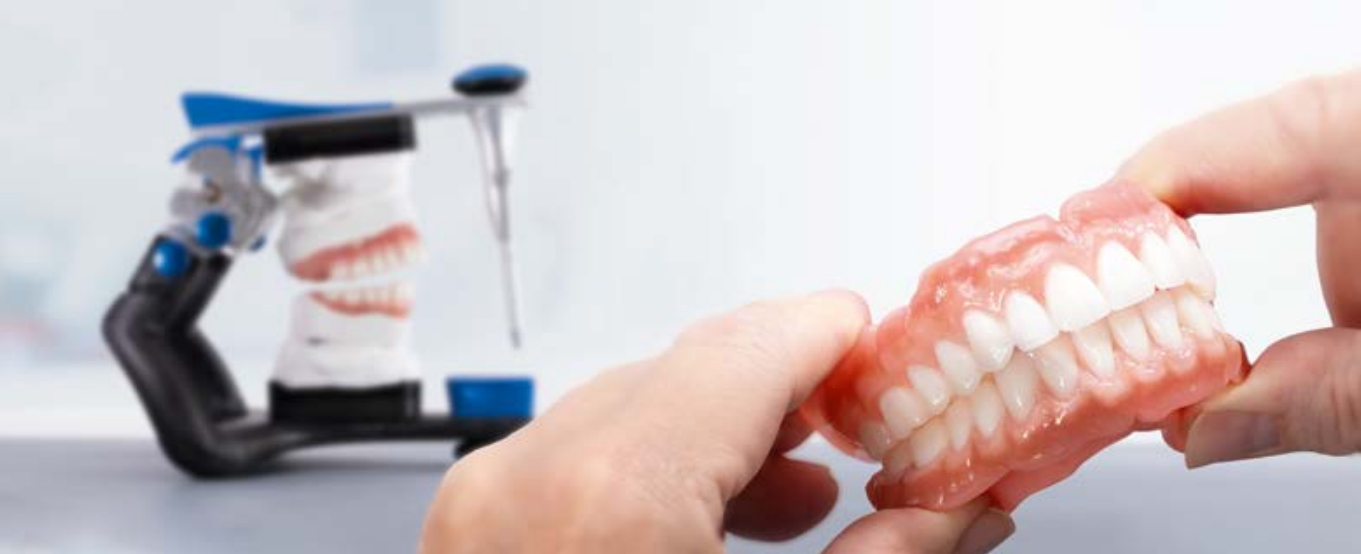

This product group is available in the VITA SYSTEM 3D-MASTER and VITA classical A1 – D4 shades. Shade compatibility with all VITA 3D-MASTER and VITA classical materials is guaranteed. With the unique VITA SYSTEM 3D-MASTER, all natural tooth shades can be systematically determined and perfectly reproduced.



Further information on
VITA MFT

www.vita-zahnfabrik.com/en/VITA-MFT



VITA MFT®

 **VITA Zahnfabrik H. Rauter GmbH & Co. KG**

Spitalgasse 3
79713 Bad Säckingen
Germany

Phone: +49 7761 562-0
Hotline: +49 7761 562-222

info@vita-zahnfabrik.com
www.vita-zahnfabrik.com

**Follow us on
social media!**



1963E_0124_V04